

MONITORING RESPIRATORY FUNCTION: CAPNOGRAPHY FOR CATS

Capnography is a true respiratory function monitor and can allow anesthetists to recognize apnea, hypoventilation, equipment malfunction and endotracheal tube obstruction. Normal arterial CO₂ is 35 – 45 mmHg. Hypoventilation is defined as an arterial CO₂ greater than 45 mmHg, meaning that CO₂ is accumulating in the patient's blood due to impaired removal or increased production. When CO₂ rises, blood pH decreases resulting in respiratory acidosis. Other adverse physiologic consequences of abnormally high levels of CO₂ include tachycardia, arrhythmias, vasodilation, increased intracranial pressure, as well as respiratory, cardiovascular and CNS depression.

Capnographs measure CO₂ in exhaled and inhaled gases and display a waveform of the partial pressure of CO₂ throughout the breath cycle. End-tidal CO₂ monitoring is a non-invasive means of estimating arterial CO₂. Under most circumstances (healthy pet, no chest surgery) end-tidal CO₂ is typically 5 – 10 mmHg less than arterial CO₂. The CO₂ waveform is a valuable tool for detecting leaks in the anesthetic system, rebreathing of CO₂ and endotracheal tube obstruction.

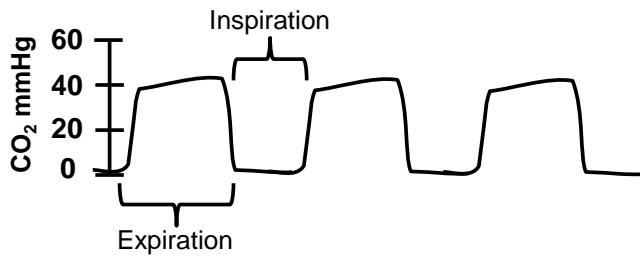
There are two different types of capnographs. Side-stream capnographs withdraw a continuous sample of respired gases from the (side of the) anesthetic circuit and transport it to a monitor for analysis. Mainstream capnographs have a sensor that measures CO₂ in respired gases in the (main stream of the) anesthetic circuit. Regardless of monitor type, purchase one that displays a waveform!

Because it takes time for exhaled gases to reach a side-stream monitor, the measurements and display are delayed. Gas is withdrawn from the anesthetic circuit by side-stream monitoring. It is important to know how much is withdrawn per minute. Monitors that withdraw smaller volumes per minute (~50 ml/min) are most appropriate for cats and other small patients compared with those that remove 100 – 200 ml/min. Know that side-stream capnographs require 1) scavenging of anesthetic gases from the monitor, 2) regular calibration, and 3) a moisture trap to remove water vapor from respired gases. On the plus side, side-stream capnographs and their adaptors are typically less expensive to purchase.

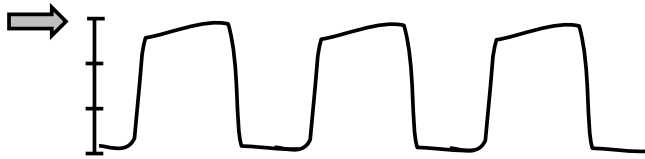
In mainstream CO₂ monitors, the measurements are performed in the sensor at the end of the endotracheal tube and, thus, have a rapid response time and are more accurate for rapid respiratory rates. No moisture trap is required for mainstream monitors and some sensors add very little dead space to the anesthetic circuit making them more appropriate for small patients. It should be noted that the expensive working end of the mainstream monitor is at the end of the ETT and should be protected.

Regardless of type of capnograph, use low dead space adaptors for patients with endotracheal tube size of 5.0 mmID or less (ie, most cats).

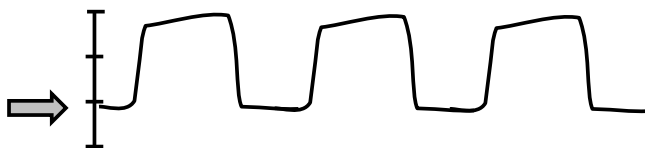Common capnography waveforms © SHAFFORD 2015



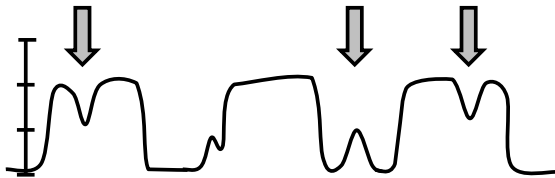
The normal capnograph is characterized by a “square” waveform that plateaus at 30 – 40 mmHg during expiration and returns to 0 mmHg during inspiration.



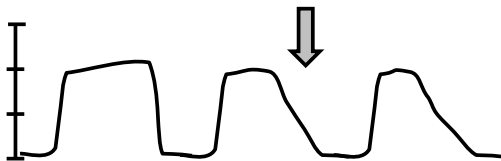
Hypoventilation is characterized by higher than normal end-tidal CO_2 , indicating respiratory depression and inefficient gas exchange. Implement treatment for hypoventilation when ETCO_2 is greater than 55 – 60 mmHg: decrease inhalant and/or initiate mechanical ventilation.



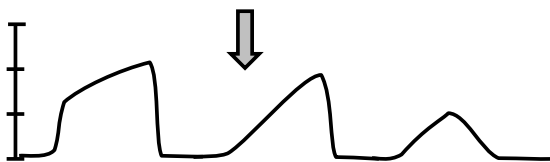
Rebreathing of CO_2 is occurring when the baseline is greater than 0 mmHg. This indicates 1) malfunctioning one-way valves, 2) exhausted soda-sorb, or 3) low oxygen flow rates in a non-rebreathing circuit. Rebreathing of CO_2 leads to acidosis and increased anesthetic depth.



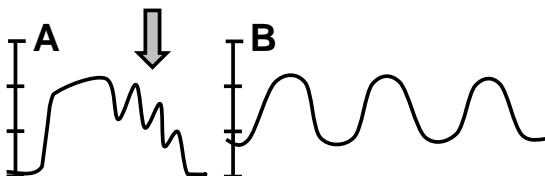
Spontaneous breathing during mechanical ventilation (i.e., patient is breathing around, or “bucking” the ventilator). This occurs if ETCO_2 is high and/or if patient is at a light plane of anesthesia. Increase anesthetic depth or increase volume/rate of ventilation to prevent spikes in pulmonary pressure from occurring.



A leak in the anesthetic circuit is indicated when the down-slope of the expiratory wave is flattened. Common sites for leaks are 1) endotracheal tube cuff, 2) junction of Y-piece & endotracheal tube, 3) junction of Y-piece & anesthetic machine, and 4) soda-sorb canister seal.



Occlusion of the endotracheal tube is characterized by a flattening of the upslope of the expiratory wave creating the appearance of “shark fins”. Check to see that the endotracheal tube is not kinked and then aspirate the endotracheal tube or remove tube and re-intubate.



A) Cardiac oscillations may be noted in large patients. The beating heart pushes on the lungs and displaces small amounts of air, resulting in small peaks in the CO_2 waveform coincident with heart rate. This is a normal finding. **B) Dilution of CO_2 sample** due to high O_2 flow, rapid respiratory rate or slow sampling rate. (artifact)